Averroes European Medical Journal
Open Access Publisher

May 2018 • Volume 3 • Number 1

ISSN: 0772-9200

ISSN (print form): 2593-1431

fMRI and cerebral tumor ablation with effect on the motor areas: Intelligent analysis

BOUHARATI Imene[1, 2] , BABOUCHE Farid[1], BOUHARATI Khaoula[1], BOUHARATI Saddek[2]

Abstract. Context: Nowadays, functional MRI is widely used in the study of brain function. If it has the advantage of being non-invasive it has several deficiencies. Zones that activate in response to a motor stimulus mislead the analyst in view of the complexity and differences between individuals and their intrinsic specificities. In the case of a brain tumor located near these areas, surgery will not be without risk on the motricity of the organ in question.

Methods: In this study, a fuzzy logic analysis is proposed. In view of the complexity of the system, the variables that define the *fMRI* images are considered as imprecise variables and thus as fuzzy variables. The motor stimulus, effect of the tumor and parasitic movements are considered as inputs to the system. The quality of the resulting image expresses the output variable. The system done, allows adjusting the input variables for an optimal image.

Results: The input or output variables are fuzzyfied. This operation makes it possible to pass numerical values to linguistic variables in the image of human reasoning. The uncertainties are compensated. The basis of the rules established from the real cases makes it possible to reproduce faithfully the state of the patient. The result at the output is a function of the input variables with the support of all possible combinations.

Conclusions: The proposed system allows locating the motor area with precision preoperatively. When the tumor affects the targeted motor zone, it will be possible to intervene with the slightest risk.

Keywords: Brain, tumor, neurosurgery, artificial intelligence, fuzzy logic.

Introduction

If the functional location is often poorly defined anatomically in people with brain diseases, it is because this is due to the effect of the tumor itself on these parts[1-5]. It is found that according to the imaging method used, the impressions of the motor areas vary in the same person. This difference can be up to 20 mm. This can be explained by the effect of the tumor on this area.

However, among the different techniques used such as functional MRI (*fMRI*), PET magnetoencephalography (MEG), and transcranial magnetic simulation (TMS), *fRMI* imaging gives the best results in preoperative planning[6]. Areas of the brain involved in motor function are localized in the primary motor cortex, lateral motor cortex, extra motor areas, subcortical areas, thalamus, cerebellum and brainstem nuclei[7;8]. The presence of a tumor near these areas can have a direct effect on motor function. This effect is exerted on the leaflets of fibers of white matter which connect these regions[9;10]. Despite the fact that surgical procedures on tumors with localization near the motor pathways are waking up for the purpose of preoperative tests, this constitutes a real risk of deterioration of the motor pathways[11].

---

1. Faculty of Medicine, Ferhat Abas Setif1 University, Algeria
2.Intelligent Systems Laboratory, University Ferhat Abbas Setif1, Setif, Algeria
Corresponding author: Bouharati Imene
Email: imene.bouharati@univ-setif.dz
Tel: +21366137459

Research done on the evolution of neurosurgery since 1980 to 2015 shows that the best results are not obtained by resection, but it provides a better understanding of the tumor nature and will guide interventions with optimal resections[12].

Given this situation, this study proposes the analysis of the functional image obtained by functional MRI in order to circumvent as much as possible the limits of the motor cerebral zones and the tumor area. Since the factors defining the image are very complex to analyze by conventional mathematical techniques, an analysis using artificial intelligence techniques is proposed. The principles of fuzzy inference are adequate in this case. The factors involved in the formation of the functional brain image by magnetic resonance are imprecise. Other factors have their effect and are totally ignored. Moreover, the images formed vary from one person to another, and also in the same person the precision is far from being acquired. Psychomotor parasites disturb the image in addition to the sensitivity of the applied magnetic field[13]. In this study, the factors supported are motor stimulus area, tumor effect, parasitic factors, are considered as inputs to the system. The quality of the resulting image including its outline expresses the output variable. A base of the rules of the form (If ... Then) is constructed and allows to adjust the input variables for an optimal image.

Characterization of interacting factors

Localization of motor brain regions

The anatomical location of cerebral cortex markers involved in movement remains essential in clinical research[14-17]. However, recent functional imaging techniques allow binding to occur in activated areas[18,19]. Functional techniques have recently made it possible to identify anatomical regions based on the correspondence with activation regions by applying morphological-binding techniques to locate the precentral gyrus[20;22]. The definition of the motor cortex corresponding to the hand, for example, is localized in MRI or CT in the form of a hook[23]. Other studies have been able to establish the definition of the bayonet or zigzag shape in the sagittal plane. Others have defined the omega form in the axial plane[24-26].

Generally, all studies using functional magnetic resonance imaging (*fMRI*) localize the area corresponding to hand movement by the axial-shaped, button-shaped precentral gyrus segment in the form of omega or epsilon[27]. All of this is confirmed by the concept of homunculus which states that the zone that activates in correspondence with the movement of the hand is located in a superior aspect of the precentral gyrus[28;30]. All these results could be confirmed by the level of blood oxygenation corresponding to activation in *fMRI* (BOLD)[31].

Effect of the tumor

An exact location and a precise definition of the effect of the tumor mass on the motor cerebral regions, make it possible to better locate the limit of the resection. This is because it has been proven that the extent of resection increases survival[32-34]. From this point on, the basic principle in brain tumor surgery is the maximum preservation of motor function after tumor resection. This implies the identification of the morphological regions in relation. However, the presence of tumors may complicate this identification by distorting the normal anatomy of these regions[35]. Therefore, the location of the tumor and its direct effect on the motor cerebral region, must also take into consideration the effect of the treatment that may contribute to the motor deficit such as a single or bilateral weakness or ataxia[36]. Successful resection involves accurate mapping of tumor-cortical and sub-cortical interaction in order to maximize an acceptable outcome[37].

Disruptive effect

Brain imaging based on cerebral oxygenation allows a better understanding of cerebral activity in different states at rest or in functional activity[38;39]. However, different disorders can alter the metabolism of oxygenation such as multi-systemic atrophy, Alzheimer's or Parkinson's[40-42]. Also, certain physiopathological situations, such as in the case of neoplasms, ischemia or neurodegenerative diseases, an imbalance between irrigation and tissue oxygen consumption is observed[43].

Add to that, the brain is considered a cognitive entity. This implies that any motor stimulus is associated with neural substrates[44-47]. Also, virtual perceptions of sensations can be associated with the excitations of the neuronal zones corresponding to the functionalities. All this can influence interpretations in neurophysiology or imaging[48]. In this context, studies have reported that activation of the motor cortex corresponding to a limb occurs even in amputees[49]. In these people one can register activations corresponding to the ghost members[50].

In addition to these factors that influence the image, other variables related to age, gender and follow-up in the duration of the tumor pathology. The phase in which the tumor is located, its size and position and its percentage in the cortex are to be taken into account.

Method

Given the complexity of this environment, the uncertainty and imprecision inherent in the imaging process in functional MRI, this study presents an intelligent analysis based on the principles of fuzzy inference. The application of the principles of fuzzy logic is adequate in this field, this because this logic deals with the uncertain and imprecise[51].

Fuzzy inference

The basic principles of fuzzy logic were first introduced by Lotfi Zadeh in 1965[52]. This logic is considered part of set theory and as such it treats linguistic variables in the image of human reasoning. In comparison with the classical binary logic which admits only two states, this one admits infinity of values between the (1) and the (0). The general rule of fuzzy logic is of the form:

If X1 IS X1(1) and X2 IS X2(2) and… Xn IS Xn(n) THAN Y1 is Y1(1).

Given its capacity to solve complex problems, this technique has found different applications, particularly in the medical field[53].

Fuzzy modeling

In this case study, a fuzzy system is built with three inputs and one output. The inputs of the system characterize the variables that influence the accuracy of *fMRI* image formation i.e., the effect of motor activation of the cortex, the effect of the tumor and the parasitic effect. The output variable represents the quality of the image formed and thus its border with the tumor mass (Figure 1).

```
[System]
Name='IRMf Tumor'
Type='mamdani'
Version=2.0
NumInputs=3
NumOutputs=1
NumRules=26
AndMethod='min'
OrMethod='max'
ImpMethod='min'
AggMethod='max'
DefuzzMethod='centroid'
```

Averroes European Medical Journal
Open Access Publisher
ISSN: 0772-9200
May 2018 • Volume 3 • Number 1

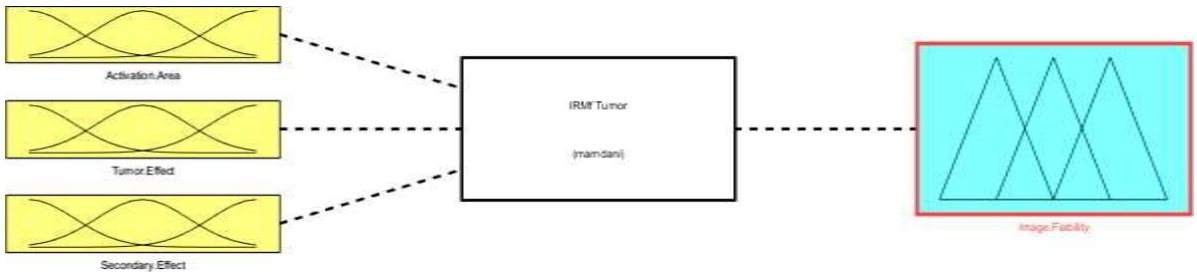

Figure 1. Block diagram of the system

Fuzzyfication of variables

This operation consists of the conversion of numerical values into linguistic variables of the human language. Each input or output variable is fuzzyfied.

Input variables

- The "Activated Zone" variable: this variable expresses the region of the activated cerebral cortex by a motor stimulus corresponding to the member concerned. This activated zone is characterized by its volume in 3D, its outlines and its shape. These distinctions are expressed by its degree of reliability in the image formed in *fMRI*. As remains relative, three membership functions are assigned over an interval that ranges from (0 to 4). In order to overcome uncertainty and inaccuracy in the assignment of membership degrees, each of two neighboring membership functions overlaps into a fuzzy domain.

Input1]
Name='Activation.Area'
Range=[0 4]
NumMFs=3
MF1='Low.Fiability':'trimf',[0 1 2]
MF2='Average.Reliability':'trimf',[1 2 3]
MF3='High.Reliability':'trimf',[2 3 4]

- The variable "Effect of the tumor": this variable expresses the effect produced by the tumor mass on the region of the cerebral cortex. The tumor mass defined by its mass, its volume, its relative position to the region of the motor cortex and the deformation it can cause on that one. Also, this variable is presented on a scale of 0 to 4. Membership functions are assigned with fuzzy intervals also to compensate for uncertainty and inaccuracy.

[Input2]
Name='Tumor.Effect'
Range=[0 4]
NumMFs=3
MF1='Low.Effect':'trimf',[0 1 2]
MF2='Medium.Effect':'trimf',[1 2 3]
MF3='Big.Effect':'trimf',[2 3 4]

- "Side effects" variable: this variable expresses the effect of other factors on the region of the cerebral cortex. These factors influence the BOLD oxygenation for example, the emotional and psychotic effect as well as the virtual effect of a motor action of a limb. This variable is represented on a scale of 0 to 4. Membership functions are assigned with fuzzy intervals as well to compensate for uncertainty and inaccuracy.

[Input3]
Name='Secondary.Effect'
Range=[0 4]
NumMFs=3
MF1='Negligible.Effect':'trimf',[0 1 2]
MF2='Medium.Effect':'trimf',[1 2 3]
MF3='Important.ffect':'trimf',[2 3 4]

Output variable

- The output variable "Image reliability": this variable expresses the degree of confidence of the *fMRI* image formed. The result is obtained by aggregating the set of input values. After defuzzyfication

by using Mamdani method, the obtained numerical result can be reassigned to the corresponding interval to read the degree of confidence in linguistic terms.

[Output1]
Name='Image.Fiability'
Range=[0 4]
NumMFs=3
MF1='Low.Fidelity':'trimf',[0 1 2]
MF2='Average.Reliability':'trimf',[1 2 3]
MF3='High.Reliability':'trimf',[2 3 4]

Rules of inference

The rules are of the form: If ... Then. Thus, these rules are established by the human expert according to the real data recorded.

Example:

If 'activated area' is of 'high reliability' AND 'effect of tumor' is 'negligible' AND 'side effects' are 'negligible' THEN 'image fidelity' is 'high'.

The base of the rules must contain all possible combinations.

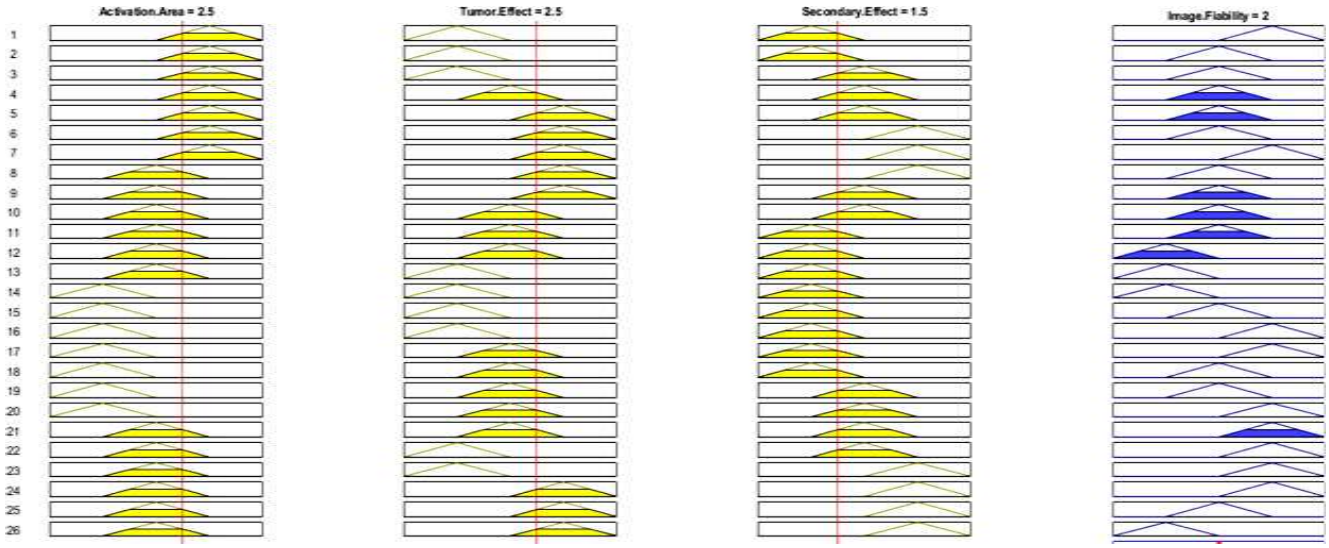

Figure 2. Application example

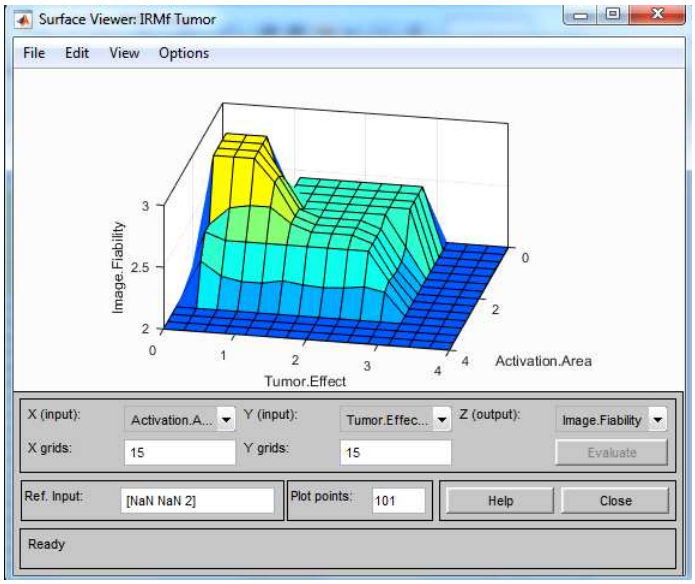

Figure 3. View surfaces

Averroes European Medical Journal
Open Access Publisher
ISSN: 0772-9200
May 2018 • Volume 3 • Number 1

Result and discussion

Once the rule base established by the expert takes into consideration all possible combinations from real cases, the system calculates the output value by taking care of all the weaknesses related to the complexity of the system. It is then sufficient to introduce random values at the input to instantly read the result at the output (Figure2). The numerical values displayed correspond to the intervals already defined in the fuzzyfication section. By this, in addition to the numerical value displayed in the sort (2 in this example), this value refers to the interval corresponding to the fuzzyfication of the output variable above. Referring to these ranges the value (2) corresponds to a medium degree of confidence.

These same variables can be illustrated in Figure 3. In this figure, it is noted that it is possible to visualize the variation of the degree of reliability of the image obtained in functional MRI as a function of the two variables (tumor effect and activated area). It is also possible to vary these factors to visualize the effect of each on the degree of confidence in the recorded image.

Conclusion

If *fMRI* has the advantage of being non-invasive and allows delimiting the zones are activated with each stimulus in 3D, it has several deficiencies. Several factors intervene in the precision of the regions of the cerebral cortex. These areas are the subject of several influences including the nature and position of the tumor relative to it. The psychotic effects that are specific to each individual disturb these activations and mislead the analyst. Also, the technique itself has a high sensitivity of the applied magnetic field, which makes it even more vulnerable to spurious signals. Mathematical analysis of such phenomena is very difficult, if not impossible. This study presents an intelligent technique using fuzzy logic. This technique fits perfectly on this case. By considering the factors involved in this process as fuzzy and therefore uncertain variables, the inadequacies are compensated. When the rule base is established by an expert from the real values, considering all possible combinations, the result will be as close to accuracy as possible.

From such a preoperative result, the neurosurgeon can have an idea about the limits of the tumor ma ss and its contact with the motor regions involved. This will give more chance of a successful postoperative recovery without collateral damage. This tool can be a diagnostic aid.

No conflict of interest

Averroes European Medical Journal
Open Access Publisher
ISSN: 0772-9200

References

1) 1) Alkhadi H., Kollias S.S., Crelier G.R., et al., Plasticity of the human motor cortex in patients with arteriovenous malformations: a functional MR imaging study. Am.J. Neuroradiol. 2000; 21, 1423–1433.
2) Carpentier A.C., Constable R.T., Schlosser M.J., et al., Patterns of functional magnetic resonance imaging activation in association with structural lesions in the rolandic region: a classification system. J. Neurosurg. 2001; .94, 946–954.
3) Duffau H. Acute functional reorganization of the human motor cortex during resection of central lesions: a study using intra operative brain mapping. J. Neurol. Neurosurg. Psychiatry 2001; 70, 506–513.
4) Mesulam M.M. Principles of Behavioral and Cognitive Neurology. Oxford University Press, Oxford, 2000; pp. 102–140.
5) Rutten G.J., Ramsey, N.F. The role of functional magnetic resonance imaging in brain surgery. Neurosurg. Focus. 2010; 28, E4.
6) Bob L. Hou, Sanjay Bhatia, Jeffrey S. Carpenter. Quantitative comparisons on hand motor functional areas determined by resting state and task BOLD fMRI and anatomical MRI for pre- surgical planning of patients with brain tumors. NeuroImage: Clinical 11. 2016; 378–387
7) Middleton FA, Strick PL. Basal ganglia and cerebellar loops: motor and cognitive circuits. Brain Res Brain Res Rev. 2000; 31:236–250
8) Dum RP, Strick PL. Motor areas in the frontal lobe of the primate. Physiol Behav. 2002; 77:677–682
9) Ward NS, Newton JM, Swayne OB, Lee L, Thompson AJ, Greenwood RJ, Rothwell JC, Frackowiak RS. Motor system activation after subcortical stroke depends on corticospinal system integrity. Brain 2006; 129(Pt 3):809–819
10) Stinear CM, Barber PA, Smale PR, Coxon JP, Fleming MK, Byblow WD. Functional potential in chronic stroke patients depends on corticospinal tract integrity. Brain 2007; 130: 170–180
11) Talacchi A, Santini B, Casagrande F, Alessandrini F, Zoccatelli G, Squintani GM. Awake surgery between art and science. Part I: clinical and operative settings. Funct Neurol 2013; 28: 205-21
12) Belsuzarri TAB, Sangenis RMA, Araujo JFM. Brain tumor surgery: supplemental intra operative imaging techniques and future challenges. J Cancer Metastasis Treat 2016; 2:70-9
13) Bouharati Imene, Babouche Farid, Bouharati Saddek. Radiography and Risk Factors of Lung Cancer: Modeling Using an Intelligent System. Int J Radiol Radiat Ther 2017; 3(5): 00074
14) Cunningham DJ. Contributions to the Surface Anatomy of the Cerebral Hemispheres. Dublin, Ireland: Academy House; 1892
15) Dejerine J. Anatomie des Centres Nerveux. Vol 1. Paris, France: Rueff; 1895
16) Testut L. Traite d'Anatomie Humaine. Paris, France: Octave Doin et Fils; 1911
17) Ono M, Kubik S, Abernathey CD. Atlas of the Cerebral Sulci. New York: Thieme; 1990
18) Hlustik P, Solodkin A, Gullapalli RP, et al. Somatotopy in human primary motor and somatosensory hand representations revisited. Cereb Cortex 2001;11:312–21
19) Hanakawa T, Parikh S, Bruno MK, et al. Finger and face representation in the ipsi lateral pre- central motor areas in humans. J Neurophysiol 2005; 93:2950–08
20) Kido DK, LeMay M, Levinson AW, et al. Computed tomographic localization of the precentral gyrus. Radiology 1980;135:373–77
21) Rumeau C, Tzourio N, Murayama N, et al. Location of hand function in the sensori motor cortex: MR and functional correlation. AJNR Am J Neuroradiol 1994;15:567–72
22) Naidich TP, Valavanis AG, Kubik S. Anatomic relationships along the low middle convexity. Part I. Normal specimens and magnetic resonance imaging. Neurosurgery 1995; 36:517– 32
23) Salamon G, Martini P, Ternier F, et al. Topographical study of supra tentorial brain tumors. J Neuroradiol 1991;18:123–40
24) Talairach J, Tournoux P. Referentially oriented cerebral MRI anatomy. New York: Thieme; 1993
25) Naidich TP, Brightbill TC. The pars marginalis: Part I: A 'bracket' sign for the central sulcus in axial plane CT and MRI. Int J Neuroradiol 1996; 2:3–19
26) Puce A, Constable RT, Luby ML, et al. Functional magnetic resonance imaging of sensory and motor cortex: comparison with electrophysiological localization. J Neurosurg 1995; 83:262–70
27) T. A. Yousry, U. D. Schmid, H. Alkadhi, D. Schmidt, A. Peraud, A. Buettner and P. Winkler. Localization of the motor hand area to a knob on the precentral gyrus A new landmark. Brain. 1997; 120, 141–157

Averroes European Medical Journal
Open Access Publisher

Averroes European Medical Journal
Open Access Publisher
ISSN: 0772-9200

28) Foerster O. Motorische Felder und Bahnen. In: Bumse H, Foerster O, eds. Handbuch der Neurologie. Berlin, Germany: Springer-Verlag; 1936; 1–37
29) Penfield W, Boldrey E. Somatic motor and sensory representation in the cerebral cortex of man as studied by electrical stimulation. Brain 1937; 60:389–443
30) Penfield W, Rasmussen T. The cerebral cortex of man. New York: McMillan; 1950
31) Yousry TA, Schmid UD, Alkadhi H, et al. Localization of the hand motor area to a knob on the precentral gyrus: a new landmark. Brain 1997;120:141–57
32) Lacroix M, Abi-Said D, Fourney DR et al. A multivariate analysis of 416 patients with glioblastoma multiforme: prognosis, extent of resection, and survival. J. Neurosurg. 2001; 95(2), 190–198.
33) Sanai N, Berger MS. Extent of resection influences outcomes for patients with gliomas. Rev. Neurol. (Paris) 2011; 167(10), 648–654
34) Kalkanis SN, Kondziolka D, Gaspar LE et al. The role of surgical resection in the management of newly diagnosed brain metastases: a systematic review and evidence-based clinical practice guideline. J. Neurooncol. 2010; 96(1), 33–43.
35) M. Caulo, C. Briganti, P.A. Mattei, B. Perfetti, A. Ferretti, G.L. Romani, A. Tartaro, C. Colosimo. New Morphologic Variants of the Hand Motor Cortex as Seen with MR Imaging in a Large Study Population. AJNR Am J Neuroradiol 2007; 28:1480–85
36) Christina Amidei David S. Kushner. Clinical implications of motor deficits related to brain tumors. Neuro-Oncology Practice, 2015; V2, Issue 4, 179–184, https://doi.org/10.1093/nop/npv017
37) Stephen T. Magill, Seunggu J. Han, Jing Li, and Mitchel S. Berger. Resection of primary motor cortex tumors: feasibility and surgical outcomes. J Neurosurg December 2017; 1-12
38) Gray LH, Conger AD, Ebert M, et al. The concentration of oxygen dissolved in tissues at the time of irradiation as a factor in radiotherapy. Br J Radiol 1953; 26:638–48
39) Brown JM, Wilson WR. Exploiting tumor hypoxia in cancer treatment. Nat Rev Cancer 2004; 4:437–47
40) Ishii K, Kitagaki H, Kono M, et al. Decreased medial temporal oxygen metabolism in Alzheimer's disease shown by PET. J Nucl Med 1996; 37:1159–65
41) Karimi M, Golchin N, Tabbal SD, et al. Sub thalamic nucleus stimulation- induced regional blood flow responses correlate with improvement of motor signs in Parkinson disease. Brain 2008; 131(pt 10):2710–19
42) Beal MF. Mitochondria, oxidative damage, and inflammation in Parkinson's disease. Ann N Y Acad Sci 2003;991:120–31
43) T. Christen, D.S. Bolar, and G. Zaharchuk. Imaging Brain Oxygenation with MRI Using Blood Oxygenation Approaches: Methods, Validation, and Clinical Applications. AJNR Am J Neuroradiol 2013; 34:1113–23.
44) Izumi, S., Findley, T.W., Ikai, T., Andrews, J., Daum, M., Chino, N. Facilitatory effect of thinking about movement on motor-evoked potentials to transcranial magnetic stimulation of the brain. Am. J. Phys. Med. Rehabil./Assoc. Acad.Physiatr. 1995; 74, 207–213.
45) Kasai, T., Kawai, S., Kawanishi, M., Yahagi, S. Evidence for facilitation of motor evoked potentials (MEPs) induced by motor imagery
46) Liang, N., Ni, Z., Takahashi, M., Murakami, T., Yahagi, S., Funase, K., Kato, T., Kasai, T. Effects of motor imagery are dependent on motor strategies. NeuroReport18, 2007; 1241– 1245
47) Mizuguchi, N., Umehara, I., Nakata, H., Kanosue, K. Modulation of corticospinal excitability dependent upon imagined force level. Exp. Brain Res. 2013; 230,243–249.
48) Takashi Hanakawa Organizing motor imageries. Neuroscience Research 2016; 104. 56–63
49) Ersland, L., Rosen, G., Lundervold, A., Smievoll, A.I., Tillung, T., Sundberg, H., Hugdahl, K., Phantom limb imaginary finger tapping causes primary motor cortexactivation: an fMRI study. NeuroReport 8, 1996; 207–210.
50) Raffin, E., Mattout, J., Reilly, K.T., Giraux, P., 2012. Disentangling motor execution from motor imagery with the phantom limb. Brain 135, 582–595).
51) Bouharati Imane, Bouharati Khaoula, Bouharati Saddek and Hamdi-Chérif Mokhtar . Functional magnetic resonance imaging: fuzzy inference analysis. Radiol Diagn Imaging, 2017. Volume 1(2): 1-4. doi: 10.15761/RDI.1000111
52) Zadeh LA. Fuzzy sets Information and Control. Volume 8, Issue 3, June 1965; P: 338-353